

Research Papers



**HISTOPATHOLOGICAL STUDY OF PTYCHOBOTHRIIDAN TAPEWORM IN
FRESHWATER FISH MASTACEMBELUS ARMATUS (LECEPEDE, 1800)
FROM AURANGABAD DISTRICT (M.S).**

H .J. Wankhede
Director of Pre –I. A. S.
Training Center,
Aurangabad.

U .P. Aade
Department of Zoology,
Dr. Babasaheb Ambedkar
Marathwada University,
Aurangabad,

K.D. Kaldate
Department of Zoology,
Dr. Babasaheb Ambedkar
Marathwada University,
Aurangabad,

Abstract

The freshwater fish Mastacembelus armatus (Lecepede, 1800) collected from Aurangabad district during the period of June 2011 and after dissection their intestinal passage was examined for cestode parasite. The tapeworm Senga sp.(Dollfus 1934) was recovered from intestine Betta splendens. Histopathological study has been made to assess the extent of damage caused by the parasite. Histological changes include destruction and extrusion of the intestinal villi, fibroblast cell and plasma cell.

KEYWORDS: Histopathology, Senga sp., Mastacembelus armatus, Intestinal villi

INTRODUCTION

Fishes are said to be gold in water, they play an important role in nation's economy. As a nutritional point of view, fishes give high content of proteins to the daily growing population. Now a day they are facing the problems of malnutrition. The tapeworms present in them cause considerable damage. The parasitic infections are very common to the man (Sushil Jawale 2011) The presence of large population of a particular species of fish provides ample habitats for parasites and the stress conditions associated with such crowding will also affect the health and subsequent susceptibility of the fish to parasites.(Jaywant Dhole 2011)

Parasites are affected by both the macro and micro environments. The environmental factors are important in the recruitment, transmission, colonization, fecundity and survival of both the adult and larval parasites (Esch et al.1977) .The cestode Senga sp. is one of the tapeworm which cause the servers damage to

Mastacembelus armatus which results into the anemia, weight loss and decreased production.

The pathogenicity of cestode adjacent various order described by (Rees, G.in 1967) study of host parasite relationship described in fishes (Mcvicar 1972) Acanthobothrium, Phillobothrium, Echinobothrium, (Murlidhar and Shinde 1987) observed histopathology of Acanthobothrium uncinatum from the fish Rhynchobatus ajeddensis (Borucinska and Caira 1993)Subsequently described the histopathogenicity of two adult Trypanorhynch from the muscosa of the nurse shark.

Never the less quit of few reports on the pathogenicity of cestode on fishes are available i. e (Sindernann 1970, Bylund 1972) . In this fist investigation we studied the histopathology of fish by cestode m. armatus (Lecepede, 1800)

MATERIALAND METHODS

For the histopathological study, M. armatus

of freshwater fishes were collected from local fisherman of Aurangabad district during the period of June 2011. These fishes were brought to the laboratory, dissected out the intestine, examined for the cestode infections. Some fishes were found to be infected whereas few were not. Both infected and non infected hosts intestine were fixed in Bouin's fluid to study histopathological changes. The fixative inhibits the post mortem changes of the tissues. Then tissues were washed, dehydrated through alcoholic grades, cleared in Xylene and embedded in paraffin wax (58-62°C). The blocks were cut at 7µ by rotary microtome and slides were stained in Eosin Haematoxylin double staining method and the sections were mounted in the DPX. Best slides or sections were selected and observed under the microscope for histopathological study. The photomicrographs were taken with the help of camera. These slides were identified by using keys "Systema Helminthum" (Yamaguti, 1956).

RESULTS AND DISCUSSION

From the present communication the results indicate that some of the intestines were found to be infected with cestode parasite. The (Plate No. A) Shows the healthy intestine, in which villi and all layers are clearly observed, where as in (Plate No. B) Infected intestine shows that the worm attached to the mucosal layer of intestine and slowly invades to the deeper. The worm senga sp, damage to various layers of the intestine right from mucosal membrane to the muscularis layer. The intestine where extensive damage caused to the villi. The villi are erupted at certain region of intestine. The result of this infection causes the intrusion of muscularis layer where the submucous membrane is totally shrunk.

The other histopathological changes observed in the intestine of *m.armatus* shows that *Senga sp* causing damage the epithelium. Dilatation of blood vessels. degeneration of intestinal folds, epithelial cell vacuolation of submucous cells and proliferative change which lead to the degeneration of various layers of the intestine are evident. mucous layer the parasite also caused the dilation of blood vessels in the submucosa results degeneration of intestinal folds, shrinkage of villi. The pathological effects include an increase in the thickness and the damage to the mucosa. The parasitic infection in turn disturbs the metabolic pathways. (Esch GW et al.1977). *Senga sp* damage the epithelial layer these results are matching in accordance with the studies carried out by (Gopal Krishnan 1968)

The Atlantic salmon (*Salmo salar*) had an anisakid larva partly embedded in the wall of an intestinal caecum (Hammerschmidt, K., 2007). However, the helminthes crosses majority of the intestinal layers (internal epithelium, submucosa, muscularis layer) and come to lie near serosa suggesting that, it is very dangerous and destructive parasites to the definitive host (C. J. Hiware, 2008)

Observations:

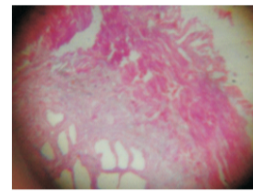


Plate A: Normal intestine of *M. armatus*

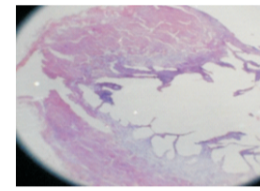


Plate B: Infected intestine of *M. armatus*

CONCLUSION:

It is concluded that the *Senga sp* cestode contact with host tissue and utilize the nutritive material to the favorable for its nourishment and growth from the host tissue and make host weak. affecting the growth of host causing damage to intestinal tissue of host.

ACKNOWLEDGEMENT

The author is very much thankful to the Head, Department of Zoology, Dr. Babasaheb Ambedkar Marathwada University, Aurangabad (Maharashtra) for providing the laboratory facilities during this work.

REFERENCES:

- 1) SUSHIL JAWALE (2011) : Biochemical studies of Caryophyllide Tapeworm in freshwater fish *Clarias batrachus*, (Recent Research in Science and Technology 2011(3):35-36
- 2) JAYWANT DHOLE (2011): Histopathological study of *Mastacembelus armatus* (LECEPEDE, 1800) infected with tapeworm from Osmanabad District (M.S.) India Recent Research in Science and Technology 2011, 3(3): 17-19
- 3) REES G. (1967) : Pathogenesis of adult cestodes Helminthol. Abstr. 36:1-23.
- 4) McVICAR A. H. (1972) : The ultrastructure of the parasite-host interface of three tetraphyllidean tapeworms of the elasmobranch *Raja naevus*

.parasitology 65:77-88.

5)MURLIDHAR,A.And SHINDE,G.B. (1987): Histopathology of the cestode, *Acanthobothrium uncinatum* (Rudolphi, 1819) from *Rhynchobatus ajeddensis* at Kakinada, A.P. India. Indian. J. of Parasitology 11(1): 85-86.

6)BORUCINSKA J.CAIRA J.N.(1993):A comparison of mode of attachment of four tapeworm species representing two order infecting the spiral intestine of the nurse shark, *Ginglymostoma cirratum*.j.parasitol.79: 238- 246.

7)SINDERMANN.C.J. (1970) :principal diseases of marine fishes and shellfish academic press New York 369 pp

8)BYLUND ,G (1972) : Pathogenic effects of *Diphyllobothrium plerocercoid* on its host fishes *commentationes biologicae, societates scientiarum fennicae* 58.1-11

9)YAMAGUTI, S. (1956): *Systema Helminthum* Vol-II. The cestode of vertebrates. Interscience publ. New York and London, 1-860.

10)Esch GW, Hazen TC, Aho JM (1977): Parasitism and r/K-selection In: GW Esch (ed), Regulation of parasite populations. Academic Press New York p 9-62

11)GOPAL KRISHNANA, V.(1968): Diseases and parasites of fishes in warm water ponds in Asia and the far East, fisheries. Report.FAO-UN 445: 319-343. (Proceedings of the 10th world symposium on warm water pond fish culture).

12)HAMMERSCHMIDT K. (2007): Establishment of Tapeworms in sticklebacks- fast food or fast lane? *Experimental Parasitology*. 116: 142-149.

13)C.J. HIWARE et. al, (2008): Studies on Histopathology of *Clarias batrachus* (Linnaeus) Intestine Parasited by Cestode, *Lytocesus clariasae* Jadhav and Gahvane, 1991 *Journal of Yala Rajabhat University*

14)DOLLFUS (1934) (1934): Sur un cestode *Pseudophyllidae* parasite de poisson ornamental *Bull. Sac. Zool. France* 69; 476-490..